

-Gaining Vertical Dimension for the Deep Bite Restorative Patient

Robert L. Lee, D.D.S., and Gary G. Gregory, D.D.S.**

Some of the most perplexing problems that the restorative dentist is called upon to treat involve those of the Class II deep bite patient. Class II deep bites are usually hereditary or are problems associated with growth or habit. Others have developed during adult life as a result of posterior teeth being lost or worn down, with subsequent tooth drift. These patients usually display a significant loss of vertical dimension, and this should be corrected in order to treat the patient successfully.

Some of the more common clinical features observed in the Class II deep bite patients which require dental intervention are: (1) temporomandibular joint syndromes with possible joint pain, tinnitus, clicking, vertigo, and sometimes loss of hearing; (2) tension and tiredness in facial and masticatory muscles; (3) periodontal disease; (4) labial migration of the upper incisors; (5) poor profile and poor esthetics with an adverse psychological and aging effect on the patient; (6) disruption in phonetics; (7) impingement of lower incisors on palatal tissue or upper incisors on labial tissue, and finally, (8) the lack of proper anterior tooth position for good incising function and for protection of the posterior teeth from excessive lateral and protrusive stress.

Although it is not difficult to diagnose the poor esthetics, phonetics, and pathologic conditions of the gnathic system observed in these deep bite patients, it is often difficult to reduce the situation to a state in which the destruction will cease and at the same time achieve a good functional and esthetic result.

Many dentists have restored deep bite conditions at the collapsed vertical dimension which the patient presented. Often the temporomandibular joint and periodontal degeneration still progressed, the maxillary anterior teeth continued to migrate labially and separate, and the over bite continued to deepen. The discouraging results in many instances

* Research Associate, World Life Research Institute, Dental Division, School of Tropical and Preventive Medicine, Colton, Calif.

might have been avoided had the restoration achieved a more correct vertical dimension.

It is necessary to increase the vertical dimension in order to help solve each of the previously mentioned problems. For instance, an accepted initial treatment of the temporomandibular joint syndrome includes increasing vertical dimension with some type of occlusal splint. Increasing vertical dimension often helps to relieve tense, tired muscles by correcting the physiological length of the muscles. Vertical dimension must be increased in order to correct overclosure of the mandible and make possible improved esthetics and phonetics. Moving the flared maxillary incisors and canines lingually or unraveling the crowded mandibular incisors requires a greater vertical dimension. There must be an increase in the vertical dimension to gain space in which to move the teeth in order to prevent the incisal edges of the lower anterior teeth from striking the palatal soft tissues. More vertical dimension is needed so that the upper anterior teeth can be coupled properly with the lower anterior teeth to help reduce the destructive forces on the teeth and periodontium.

There are three disciplines in dentistry which may be employed to help gain the vertical dimension necessary in treating these patients: orthodontia, oral surgery, and restorative dentistry; sometimes a combination of the three is required. It is not within the scope of this article to present techniques for treating orthodontically when little or no restorative dentistry is necessary or to discuss those cases of gross malocclusion in which surgery is indicated. These patients are usually treated by specialists or specially qualified restorative dentists. This article presents concepts and techniques for the restorative dentist in positioning and restoring the teeth at an adequate vertical dimension to help solve many of the problems encountered in these cases.

The question that immediately arises is: How does one determine the degree of vertical dimension to which a particular patient should be restored? The answer is that the desired vertical dimension is dictated by the requirements necessary to solve the problems of the individual patient. More specifically, we must gain enough vertical space to move the incisal edges of the lower anterior teeth away from the irritated palatal tissues so that they will rest on the cingula of the maxillary incisors sufficiently so that they cannot gradually force their way back into the palate. This position has usually been found to be near the deepest portion of the lingual fossae of the upper incisors. In some patients we find the maxillary incisors are positioned so far labially that the lower lip rests between the upper and lower incisors, thus forcing the upper incisors even farther labially. In some cases, the vertical dimension should be increased sufficiently to allow the lingual fossae of the upper incisors to be brought

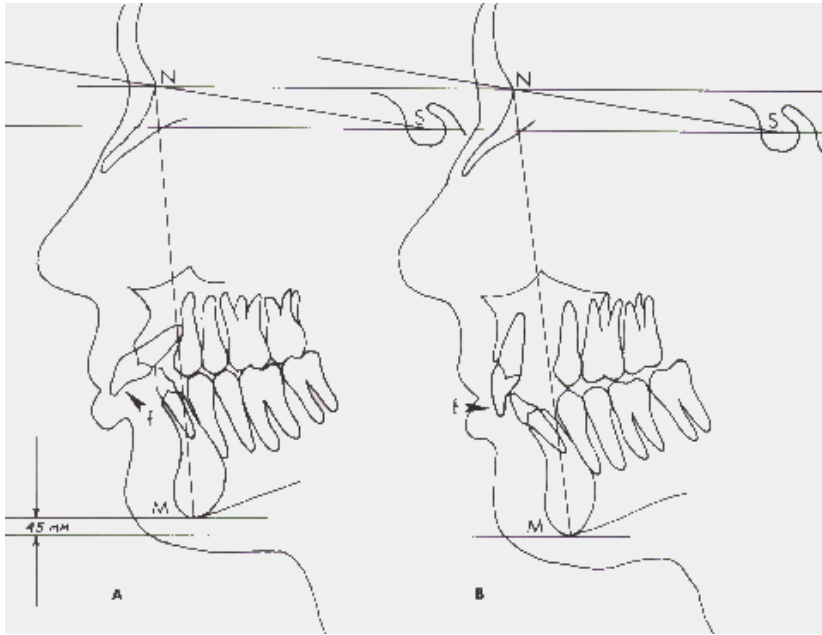


Figure 1. Cephalometric tracings of before and after orthodontic treatment on a 53-year old female patient. In *A*, note the poor lip profile. The lower lip acts as an orthodontic force (*F*) to protrude the upper anterior teeth. In *B*, the upper anterior teeth have been orthodontically positioned so that the lower lip now acts to hold the upper anterior teeth back against the lower anterior teeth. Note also the improved inclinations of the anterior teeth (*B*) and that the lower anterior teeth contact the lingual fossae of the upper anterior teeth when the jaws are in centric relation. A system of coordinates based upon the *S*, *N*, and *M* points show the actual increase in vertical dimension to be 4.5mm. The space between the posterior teeth in *B* will be occupied by restorations when the case is completed. Mounted casts of this patient are shown in Figure 8.

into contact with the incisal edges of the lower anterior teeth. This allows the lower lip to rest against the labial surface of the upper incisors to hold them lingually (Fig. 1). Furthermore, we should open a sufficient amount to relieve any temporomandibular joint stress or muscle fatigue due to overclosure. We should increase the vertical dimension a sufficient amount to gain space in which to move the anterior teeth into proper functional position. This position is one in which the canines and incisors receive all tooth contacts in eccentric jaw movements. We should increase the vertical dimension enough to establish adequate space to retain or gain normal length to the clinical crowns of the anterior teeth; this is essential for good esthetics and phonetics.

In order to accomplish these goals, it is obvious that more vertical room is necessary. Increasing vertical dimension, however, accentuates the Class II characteristics (Fig 2). This is because the lower jaw rotates about the hinge axis, carrying it downward and backward and thus causing the lower anterior teeth to be even more distal to the upper anterior teeth and the molar relationships to be more in Class II than before the vertical

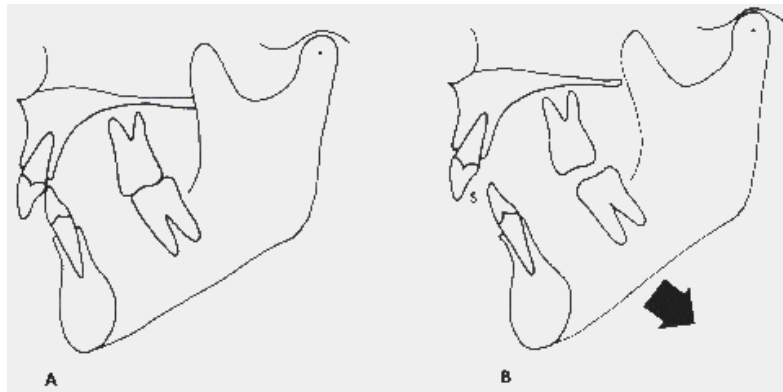


Figure 2. The relationships of the teeth in the Class II deep bite patient are shown in A. Rotation of the mandible about its hinge axis (B) results in creating a large space (S) between the upper and lower front teeth and also accentuates the Class II molar characteristics. This space must be closed in order to solve the case satisfactorily.

dimension was increased. It is this downward, backward path the mandible follows when the mouth is opened that makes it necessary in many cases to move the teeth into a more ideal position prior to restoring the mouth. If the problems of the patient can be solved with restorative procedures only, the vertical dimension is increased by fabricating the restorations at a vertical height great enough to satisfy the specific requirements of that particular patient. When orthodontia is warranted, the necessary increase in vertical dimension is accomplished gradually during the months of orthodontic treatment prior to restoring the teeth. Vertical dimension can also be increased immediately by means of various types of plastic splints or bite planes placed between the teeth.⁴ These help to free the occlusion so the teeth can be more readily moved orthodontically. When posterior splints are used, it is necessary to construct crowns and onlays that fill the space previously occupied by the splint in order to maintain permanently the new vertical dimension. This is done by increasing the clinical height of the posterior restorations. When anterior bite planes are utilized, the space created in the posterior regions can often be reduced by moving the teeth and alveolar processes occlusally by orthodontic and natural forces.

In the treatment of the adult Class II deep bite patient, the authors have found the necessary orthodontic treatment to be substantially simplified by the use of the splints placed between the posterior teeth (Fig. 3) to support the jaws at the tentative vertical dimension. Efforts can then be directed primarily to the correction of the anterior tooth relationships. The rationale for this treatment procedure is based on the fact that malpositions of the anterior teeth are extremely difficult to deal with by utilizing restorative procedures only, a method which often results in

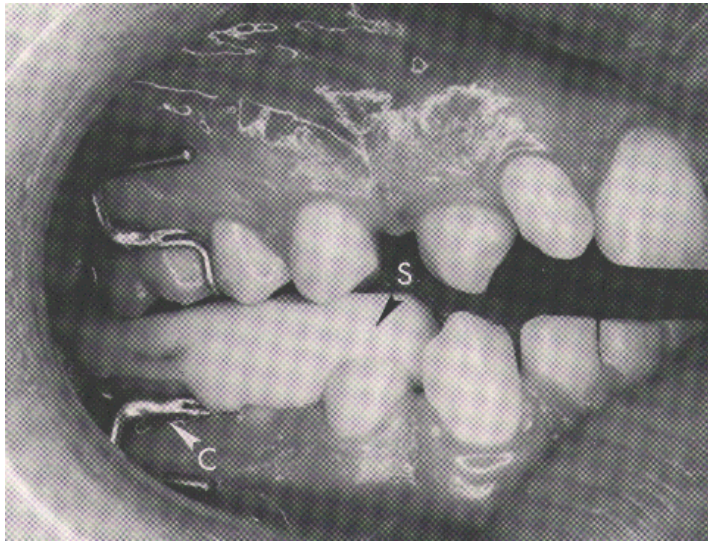


Figure 3. A plastic posterior splint (*S*) was fabricated by adding cold cure acrylic to a lower Crozat appliance (*C*). This splint supports the jaws at the tentative vertical dimension and frees the anterior teeth for easier orthodontic manipulation.

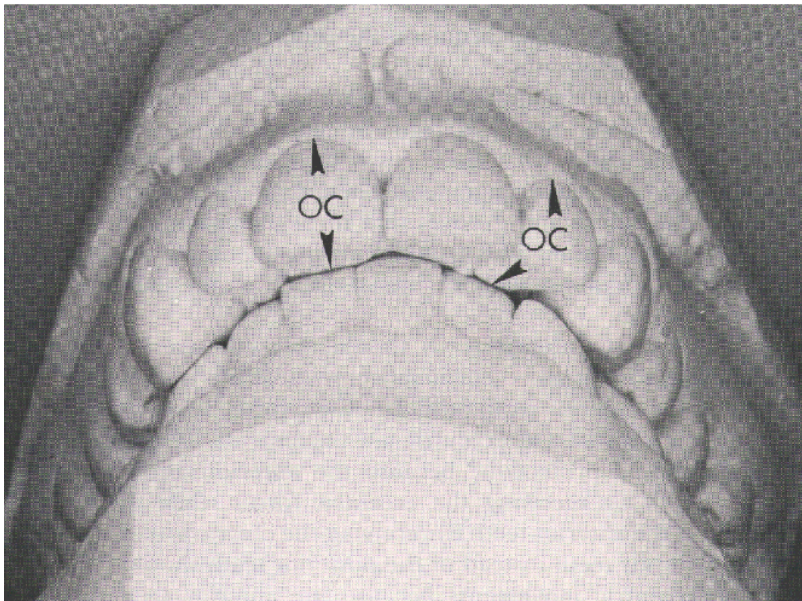


Figure 4. The upper anterior crowns of this patient had to be grossly overcontoured buccalingually (*OC*) in order to establish contact with the incisal edges of the lower anterior teeth when the jaws are in centric relation. Had these anterior teeth been moved lingually prior to restoring them this overcrowding could have been avoided.

grossly abnormal contour in the crowns (Fig. 4). On the other hand, an occlusal scheme for the posterior teeth can be worked out satisfactorily, even if the teeth are not in Class I occlusion. In these cases, the posterior teeth must be resurfaced with newly positioned cusps and fossae at the new vertical dimension. At the onset of treatment, a splint is fabricated at an arbitrary vertical dimension that is thought will be adequate for the patient at the completion of treatment. As treatment progresses, the arbitrary vertical dimension may need to be altered in order to satisfy the specific requirements of the individual patient. This concept will be discussed in more detail later.

Prior to a discussion of diagnosis, treatment planning and the specifics of treatment, the reader should understand the basic concepts of what the authors consider to be a good occlusal scheme for these patients.¹

OCCLUSAL REQUIREMENTS

1. The teeth in the lower arch should simultaneously contact the teeth of the upper arch when the patient closes in terminal hinge position with both condyles seated comfortably in their respective fossae (centric relations)
2. The arch form and tooth position should ensure that the crowns of the teeth are properly placed over their roots so that the stress of closure will exert minimal torque on the teeth and thus help minimize stress to the periodontium.
3. There should be multiple occlusal contacts of the upper posterior teeth with the lower posterior teeth in centric relation. The occlusal contacts of the fossae that hold cusps (lingual of uppers, buccal of lowers) have a tripodal arrangement. These tripodal contacts are on the inclines of the ridges and grooves that form the fossae rather than at the depth of the fossae. This tripodal arrangement prevents the teeth from shifting buccal-lingually or desial-distally as the mandible closes in centric relation.
4. The upper anterior teeth should correctly overlap the lower anterior teeth so that all eccentric movements of the jaw result in tooth contacts of the anterior teeth only. In other words, there should be no posterior tooth contacts in eccentric jaw movements. This arrangement is called "mutual protection" because the anterior teeth protect the posterior teeth by receiving the eccentric forces while the posterior teeth protect the anterior teeth by receiving the centric forces.

The anterior teeth instead of the posterior teeth should handle the forces of eccentric movements because the anterior teeth are positioned further away from insertions of the heavy muscles of mastication and have a leverage factor to reduce the forces

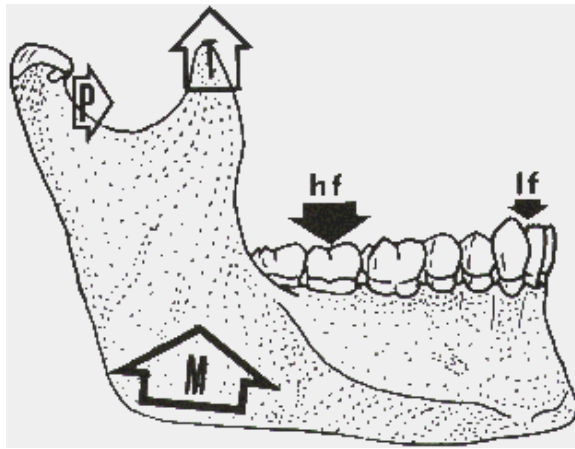


Figure 5. Illustrated are the forces of the masticatory muscles (*M.T.*, and *P*) and their corresponding ability to exert stress on the various teeth. A given muscle contraction can create heavy force (*hf*) on the anterior teeth. Because of their mechanical advantage, the anterior teeth are good candidates to withstand eccentric forces.

produced by these muscles (Fig 5). The posterior teeth do not enjoy this mechanical advantage, since they are very near the forces exerted by these muscles. The neuromuscular proprioceptors associated with the anterior teeth (nerve terminals considered to be the most sensitive in the mouth) are utilized to limit the overstress that the muscles may apply to the teeth.²

As the canines wear down over the years as a result of the lateral jaw movements, the next teeth to come into contact during eccentric lateral movements should be the premolars and then the molars on the working side. This scheme may be referred to as a “second line of defense” in our attempt to avoid the potentially destructive eccentric contacts of the posterior teeth on the non-working side of the mouth.

Although other schemes of occlusion, such as group function or cross mouth balance, may function satisfactorily in many cases, the “mutual protection” scheme is preferred in these Class II deep bite cases because it places the lateral stresses of eccentric movements on the anterior teeth, which, with their mechanical advantage, can withstand these forces. This scheme also relieves the lateral stress on the posterior teeth, where we are sometimes required to increase the crown to root ratio when establishing vertical dimension. Posterior teeth are usually considered poor candidates for handling lateral stress.

There are two basic circumstances that place stress on the teeth and peridontium. One occurs during mastication when a bolus of food is between the teeth, and the other occurs when the mouth is empty and the teeth are contacting. Many clinicians believe that it is more important to choose an occlusal scheme to accommodate the forces of clenching,

bruxing, and grinding, which occur during the large part of the day when the mouth is empty, than a scheme to withstand the forces of mastication.

Keeping in mind the Class II deep bite problems, the necessity for opening the vertical dimension to treat these patients successfully, the difficulties that increasing the vertical dimension presents, and the basic concepts of occlusion, we now present a discussion of diagnosis, treatment planning, and specific methods of treatment.

DIAGNOSIS

Because of the complexity of these cases, a good diagnosis is paramount as the first step toward treatment.

Health Evaluation

A careful history and a physical examination, combined with whatever laboratory tests may be necessary, can provide answers to the two basic questions in the health evaluation; can the patient physically withstand the trauma of treatment, and is his general health adequate to maintain the oral tissue in good condition long enough to redeem his investment? For example, a patient with uncontrolled diabetes or severe anemia would be a poor candidate for extensive treatment of this type.

Oral Evaluation

Teeth and Restoration. The conditions of the teeth require special consideration because in the patient with few restorations and few carious lesions we think in terms of total orthodontics, as opposed to extensive restorations, for gaining the desired results. This may require a longer treatment period but it is much more conservative in its effect on tooth structure than restoring the teeth. However, in the patient with extensive restorations already present and with a need for future restorations, we may elect to utilize a treatment plan in which little or no orthodontia is done. Nevertheless, positioning the teeth for better axial inclination is always desirable to improve esthetics, phonetics, and function.

Periodontal Structures. The periodontal structures must be in an acceptably healthy state before orthodontic procedures are started, if orthodontia is to be part of the treatment. In older patients there is usually some degree of bone loss as a result of prior periodontal conditions, and it should be kept in mind that there is an additional bone loss during extended orthodontic treatment. The periodontal involvement of certain teeth is more critical than that of other teeth; for instance, the canines should be relatively free from periodontal disease because when treatment is completed they must withstand a great deal of lateral stress. When restorative procedures only are used to achieve the desired vertical, the guide for periodontal conditions will be the same as in any other crown

and bridge patient. In severe periodontal cases care should be given to increase the crown to root ratio a minimal amount.

Occlusion. The patient's mandible should be placed in terminal hinge position to ascertain whether an acquired or true centric relation exists and to determine the severity of any premature contacts. The eccentric movements must also be tested to determine which teeth in the arches are stressed when the jaws move into lateral or protrusive excursions. The patient's mandible should be moved in all lateral and protrusive excursions to ascertain how the teeth contact during these movements and to determine the extent to which the teeth must be contoured or moved in order to achieve the occlusion previously described.

Arch Form and Tooth Inclination. Class II deep bite patients often have constricted arches with lingual inclination of the posterior teeth. These arches are good candidates for orthodontics to increase vertical dimension, especially when appliances of the arch expansion type are used.

Habits. It is extremely important to ascertain if the patient has a lip or tongue habit, as these habits act as orthodontic forces in themselves and often work against the dentist in his attempts to gain better positions of the teeth. It is better to train the patient to break these habits, if possible; however, it has been found that, once the teeth are repositioned and restored, these forces do not seem to disturb the new occlusion as much as once was thought.

Patients who demonstrate clenching and bruxating habits should be given special consideration if orthodontic treatment is contemplated, because clenching and truxating tends to force the teeth back into their original positions. To relieve the adverse action of interlocking cusps, splints and selective grinding are often helpful.

Radiographic Evaluation

The use of full mouth periapical radiographs and bite wings in dental diagnosis is well understood by most dentists; however, the use of panoramic radiographs can also be an extremely valuable adjunct in diagnosis, especially if endodontic stabilizers or various types of dental implants are considered. This type of radiograph is somewhat distorted but reveals a continuity of the gnathic hard structures, including the full height of the mandible and positions of the mandibular canal and of the sinuses; these are not available in intra-oral radiographs. Although cephalometric radiographs are used primarily in young patients to study and predict growth patterns, they can also be used as valuable records in adults to show inclination of teeth and where the long axis of the teeth may be when they are moved. This is especially true in determining if the

maxillary canine can simply be tipped into the position of the extracted or missing first premolar, or if bodily movement is necessary (Fig. 6).

Although photographs are not necessarily diagnostic tools, they are valuable methods of obtaining before and after records of tooth positions, profiles, esthetic conditions, and so forth. They are also helpful for study during diagnosis and treatment planning when the patient is not present.

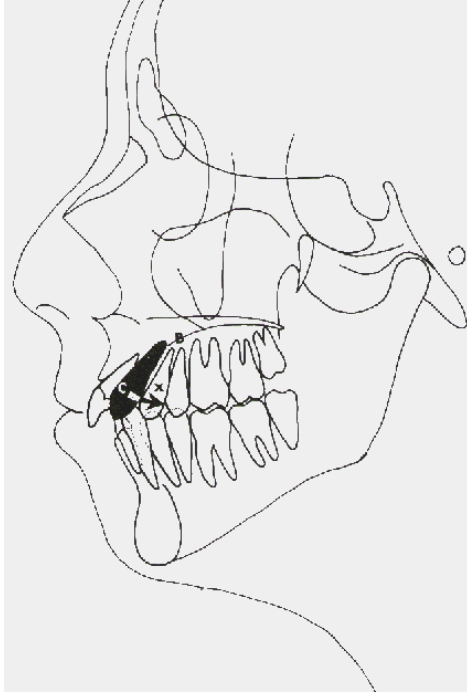


Figure 6. A cephalometric tracing showing a mesially inclined canine (*C*) with its apex near the apices of the premolars (*B*). It is sometimes expedient in these cases to extract the upper first premolars (*X*) and tip the canines distally to contact the second premolars.

Study Cast Evaluation

Since all treatment is to a hinge axis relationship, the diagnostic casts should be mounted in centric relation. It is generally accepted that the mouth is a poor place to evaluate many tooth and jaw relationships necessary for an adequate diagnosis.'

The upper cast should be mounted on the articulator by means of a face bow, the lower cast in turn is mounted with an interocclusal record taken with the patient in terminal hinge axis position, with the teeth near but not contacting. If contact is made, a certain amount of deflection will take place and an erroneous centric relation of the jaws will be produced. The semiadjustable articulator is set by using protrusive and lateral check bites and then diagnostic movements and relationships can be made on the casts without interference of muscles, lips and tongue. In addition, closed mouth relationships can be viewed from the lingual, a procedure which is, of course, impossible to do with a patient.

These mounted casts give an initial static record and also a dynamic record that can be referred to later.

Patient Evaluation

Personal Habits. Heavy drinking and smoking tend to reduce the patient's tissue tolerance to stressful treatments such as orthodontics; therefore, one may choose to gain vertical dimension by the use of purely restorative procedures in which the treatment time is much shorter and stress to the periodontium during treatment is minimized.

Oral Hygiene. Not all patients with poor oral hygiene are poor risks for extensive treatment, but it is usually the case. The dentist must try to find out if the patient is teachable and willing to change his habits, then put the patient to the test before a complex treatment plan is started. Although it is important that all restorative patients practice good hygiene, it is even more important in patients undergoing prolonged treatment or orthodontics in which there is added stress.

Psychological Stability. Although difficult to ascertain, this is important, especially when long treatment plans are being considered. Many patients are not aware of their own psychological and nervous tendencies. They may start a prolonged treatment plan in good faith and find that they are unable to withstand the added stress of wearing orthodontic appliances, and as a result want to stop treatment.

Occupation. For someone who must meet the public in his vocation, removable appliances such as Crozats may be preferable to fixed bands and head gear because they are not as conspicuous and can be removed for special occasions. The patient's economic conditions may alter the treatment plan, as cases involving orthodontic treatment are usually more costly than those with more restorative treatment.

Musculature. Facial and masticatory musculature should be noted because usually a patient with square hard-set jaws and heavy musculature is more difficult to treat orthodontially and places more stress on the periodontium and restorations.

Dental I.Q. When evaluating a patient for various modes of treatment, we should determine his dental I.Q. That is, we must find out what he knows about his specific dental problems and how readily he grasps the situation and its potentials. The dentist should determine how teachable the patient is and whether he can understand and carry out his responsibilities to the dentist.

Cooperation. Patient cooperation is another important factor to ascertain during the diagnosis phase; this is especially important if orthodontics is contemplated, because orthodontics is always more taxing to the patient than he will expect before treatment is initiated.

After all necessary diagnostic data have been collected and evaluated, a final treatment plan is made which is based on this evaluation,

the dentist's ability, and the ability of the patient. The dentist is now ready to meet with the patient for the consultation in order to gain his confidence, support, cooperation, and approval. Only then should treatment commence.

In the correction of Class II deep bite malocclusion, we must decide, in light of the diagnostic data, to treat the patient in one of the following ways:

1. Reduction of the malocclusion by utilizing orthodontic or surgical therapy only – this would involve patients needing little or no restorative dentistry. These patients are most often referred to the specialist and thus details of treatment do not fall within the scope of this discussion.
2. A number of Class II deep bite patients can be treated successfully by utilizing only restorative procedures.
3. A far greater number require a combined therapy of orthodontics followed by restorative procedures.

ORTHODONTICS AND ORAL SURGERY

In recent years there has been an increasing use of oral surgery procedures in helping to reduce gross malrelationships of the arches, especially in those cases which involve the vertical dimension. These procedures include slipping the tooth-bearing portion of the mandible either forward or backward, or moving the anterior maxillary segment into better relationship. These gross procedures are usually followed by orthodontic and restorative procedures to refine and stabilize the treatment. It is not within the scope of this article to present either oral surgery or general orthodontics as modalities in improving vertical dimension. It is generally accepted however, that orthodontics is the choice of treatment for improving vertical dimension because with orthodontics, it is possible to treat the patient during the early years of growth and development. This early intervention is intended to correct and stabilize the gnathic system and thus help prevent the need for the procedures presented in this discussion. The restorative dentist should call upon a specialist in one of these fields when it is felt that the patient can benefit from these services.

INCREASING VERTICAL DIMENSION BY RESTORATIVE APPROACH ONLY

When restorative procedures alone are utilized in treating a deep bite case, it is a relatively simple matter to gain vertical dimension by opening the lower jaw on the axis to the new vertical and then restoring

the posterior teeth by adding onlays or crowns to occlude at the new vertical level. The occlusal anatomy can be waxed and cast in an acceptable fashion and without any special difficulty, even when the teeth themselves are in Class II molar relationship – especially if the cusp-fossa ridge-groove scheme is used in conjunction with articulators that duplicate jaw movements accurately.

The problems of restoring the anterior portion of the mouth to occlude at the new vertical are not as easily solved as those in the posterior areas. This is because the dentist must deal with esthetic and phonetic problems as well as those involving function. When the mandible is rotated about the axis in gaining the new vertical, the incisal edges of the lower anterior teeth get farther away from the lingual aspects of the upper anterior teeth. Since this space creates other adverse conditions in the gnathic system, as mentioned previously, the space must be closed by some type of restorative measures. There are several methods that have been utilized in the past in attempting to solve this problem. One method is the use of a removable “stay plate.” This plate is usually some type of plastic or metal appliance that is worn on the upper arch, filling the void and creating a surface for the lower anterior teeth to contact. Another method for closing the anterior space created by the new vertical dimension is to crown the anterior teeth and reshape them. This often requires full crowns, not only on the upper anterior teeth but very often on the lower anterior teeth as well. Sometimes the maxillary central and lateral incisors were extracted and replaced with a fixed bridge from canine to canine. On rare occasions, the lower anterior central and lateral incisors were extracted as well as the uppers and replaced with fixed bridges. In some extreme cases some of the anterior teeth (usually maxillary) were extracted and replaced with a removable partial denture.

The disadvantages of extracting teeth are obvious; in addition to the loss of teeth, there is often an undesirable flattening of the parabolic curve of the dental arch in the bridge or removable partial prosthesis. This attempt to close the anterior space by moving the crown portion of the restored or replaced upper anterior teeth lingually necessitates a narrowing and often lengthening of the upper anterior replaced or restored crowns; this is esthetically bad. In addition, there is usually an overthickening of the crowns or pontics labiolingually (Fig. 4), a result which may decrease incising function and interfere with phonetics. These choices of treatment should be used only as a last resort when time or patient cooperation does not permit preresorative tooth positioning. When the vertical dimension is restored to a patient in this manner the dentist should always utilize temporary crowns or plastic splints at the new vertical height for a period of time to be sure that the restored vertical dimension is not too great for the patient to tolerate.

GAINING AND RETAINING VERTICAL DIMENSION BY A COMBINED TREATMENT

GRADUAL (TOOTH SUPPORTED) VERTICAL CHANGE

Let us consider the use of total tooth repositioning as a modality in establishing a good vertical dimension. This treatment is theoretically most ideal and conservative. It can be accomplished by various types of orthodontic appliances, ranging from the banded edgewise type to removable types such as the Crozat.

The objective with this approach is to gain a proper vertical dimension and at the same time place each remaining individual tooth in the arches in the most ideal position. In this treatment plan, the posterior teeth stop the arc of closure. As the posterior teeth are moved, there is a gradual change in the vertical dimension and consequently a space between the occluding surfaces of the anterior teeth. The upper anterior teeth are moved lingually into this space to contact the lower anterior teeth. This type of treatment probably should not be attempted by a novice, since it requires a great deal of knowledge, experience, and skill with the particular types of appliances used. This method also requires a greater investment of time by both the dentist and patient, and more cooperation on the part of the patient.

Where removable appliances such as the Crozat are used, much of the vertical dimension is gained by tipping the crowns of the teeth laterally while creating a wider arch form. Tipping the maxillary posterior teeth distally into Class I relation also increases vertical dimension. Uprighting mesially inclined or tipped over teeth, and untangling crowded lower anterior teeth by moving them labially to contact the upper anterior teeth are other ways to gain a better vertical dimension. It may be necessary to rotate, extrude, or depress certain teeth, but these factors are not as important in creating vertical dimension. The tipping actions on the teeth often work in the dentist's favor to gain vertical dimension, and at the same time the crowns of the teeth can be moved over the long axis of the roots. When the vertical dimension has been gained for a patient in this manner, the clinicians have not encountered opening the vertical beyond the physiological limits. The muscles, ligaments, and proprioceptors apparently have time to become accustomed gradually, to the changes.

The teeth are moved to their final position with the mandible in the terminal hinge position so that centric relation can be achieved. Where badly destroyed teeth exist, provisional or temporary crowns are used to support the appliances during orthodontic treatment; these provisional crowns can then be replaced with permanent restorations after orthodontic treatment is completed. If the anterior teeth are sound or few caries are

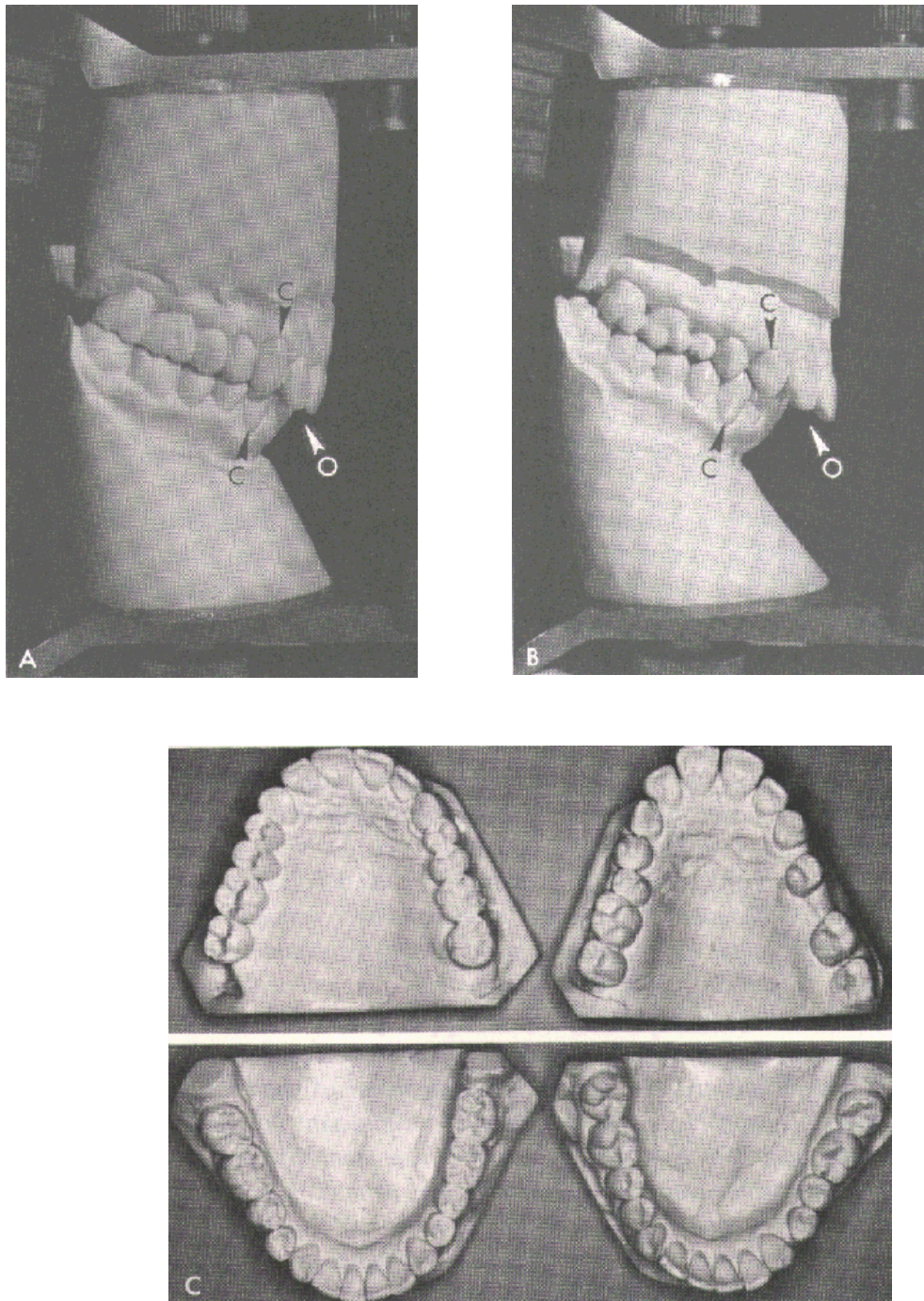


Figure 7. Post-restorative cast *A* and original casts *B* of a 43-year old male patient who was treated with Erozat appliances. Note in *A* the canines (*C*) and molars have been positioned in Class I with proper angulation. *C* shows that the constricted arches have been developed to proper arch form. During therapy the vertical dimension was gradually increased, allowing the reduction of the excessive overjet and overbite (*O*). This eliminated the necessity for crowning the anterior teeth.

present, the anterior teeth are brought into position at the new vertical so that no anterior restorations will be needed to finish and stabilize the treatment. In cases in which there have been a great number of caries and extensive breakdown of the anterior teeth, the subsequent crowns can now be properly contoured because the teeth were first moved to an ideal position. In Figure 7 the anterior teeth were moved to their final position and required no anterior restorations.

The main disadvantages to this mode of therapy are the length of treatment, often several years, and lack of patient cooperation. It is also difficult to move the posterior teeth distally while they are intercusping with the teeth in the opposite arch; however, the use of splints or bite planes help reduce this problem.

IMMEDIATE (SPLINT-SUPPORTED) VERTICAL CHANGE

This type of type of combination treatment is based upon a knowledge of gnathology and on experience gained by treating adult patients with various orthodontic appliances. The objective is to reduce the amount of time in orthodontics primarily by moving the anterior teeth to a good vertical relationship in terminal hinge position and then crowning or onlaying the posterior teeth at this new vertical dimension. The treatment also includes uprighting mesially tipped teeth caused by lost teeth, but it does not necessarily include moving the posterior teeth into Angle's Class I molar relation. It may include widening arches by moving teeth buccally, eliminating cross bites, and rotating teeth.

In Class II, Division I, patients in whom the overjet is excessive, it may be expedient to extract the upper first premolars and move the anterior six teeth lingually to reduce the overjet and gain proper anterior tooth relationships (Fig. 8). If upper premolars are extracted, the mode of moving the teeth becomes more critical. When the canines are mesially inclined and the apices are near those of the first premolars (Fig 6), then an appliance which executes only a simple tipping action can be employed; however, if the canines are near proper angulation and apices of canine and first premolar are normally spaced, then an appliance which executes a bodily movement of the teeth should be employed so that one does not create a large triangular space distal to a tipped canine.

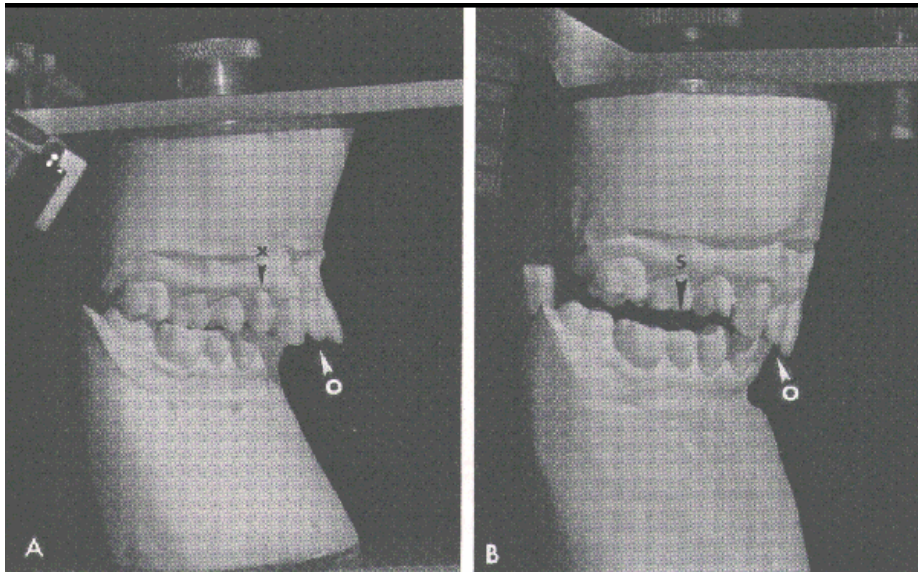


Figure 8. Axis-mounted casts of a 53-year old female patient in which the maxillary first premolars (*x*) were removed. A modified Crozat splint was used to gain vertical dimension to allow the anterior teeth to be moved into proper relationship (*B*). Restorations on the posterior teeth will occupy the space (*S*). No restorations are necessary on the anterior teeth because the overjet and overbite (*O*) were corrected with orthodontics.

Class II, Division 1 (Treatment Example)

Various methods and appliances can be used to create a new vertical dimension and improve tooth positions. The appliance shown in Figure 9 is a modified Crozat. A brief description of its use is as follows: Upper and lower appliances are fabricated in the conventional manner.³ The appliances are seated in the patient's mouth and soft acrylic resin (tooth colored) is placed on the occlusal surfaces of the lower posterior teeth (Fig. 3). The plastic is allowed to flow in and around the wires on the occlusal surfaces of the teeth so that the plastic will be held to the appliance when it is removed from the mouth. More resin is added until there is a buildup of several millimeters on the occlusal surface of the lower teeth. While the plastic is still pliable the patient's jaws are brought gently together in terminal hinge position so that indentations are made by the upper teeth in the plastic. The amount of vertical opening can be decreased by having the patient bite deeper into the plastic. Before the resin has gone through the heat stage, the appliance, with the plastic joined to it, is removed from the mouth and then replaced. To ensure that the resin does not lock in undercuts around the teeth, this procedure is

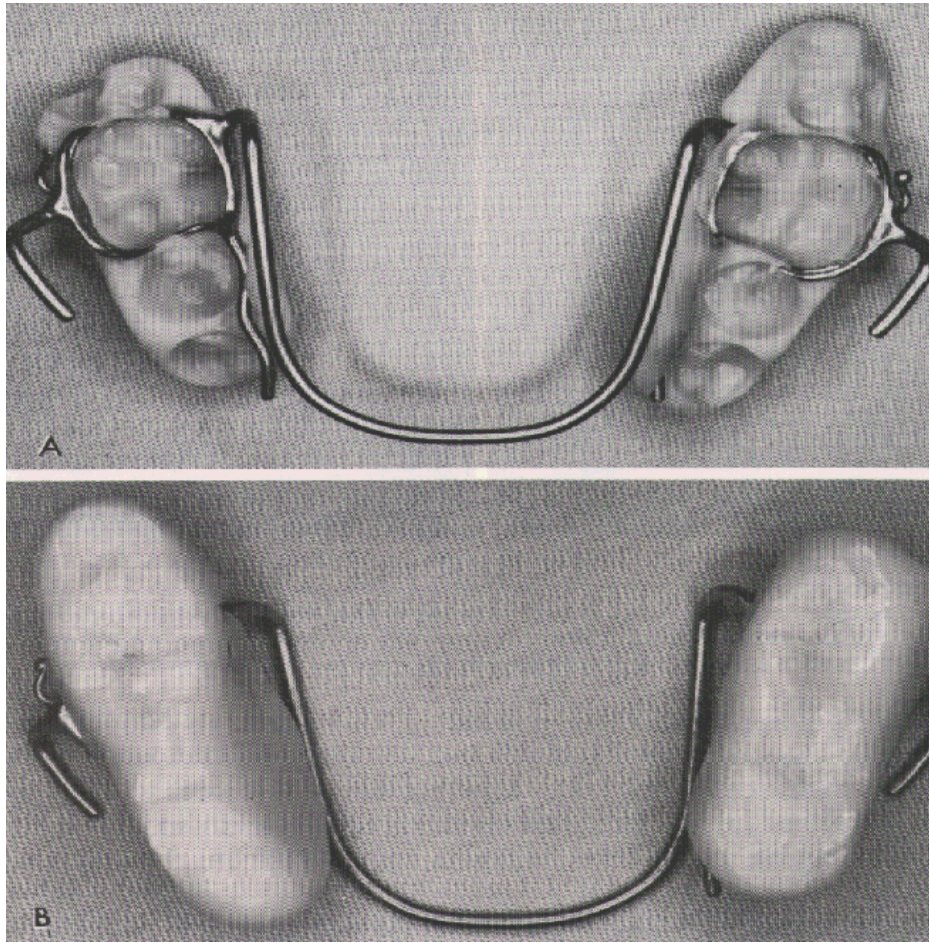


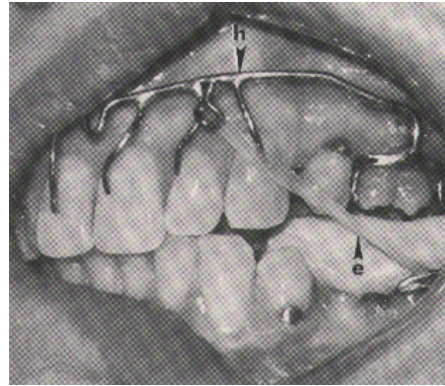
Figure 9. A lower Crozat appliance which has been modified with cold cure acrylic to function as a posterior splint. *A*, inferior view; *B*, occlusal view.

repeated several times while the plastic hardens. The plastic is then shaped with grinding tools and polished.

This type of splint creates a new vertical dimension which can be increased at any time by adding more plastic or can be decreased by grinding some of the plastic away. If the upper first premolars are to be extracted, they are removed at this time. The upper appliance must have a high labial wire with pins and putters in order to tip the upper anterior teeth backwards into the space that was created by extractions. Even though the indentations in the splint made by the upper teeth help to keep the upper posterior teeth from moving forward, reciprocal pressure in the form of Class II interarch elastics is also essential (Fig. 10). These elastics are fastened to hooks at the canine areas on the upper labial wire and run back to buccal hooks on the lower appliance in the molar areas. As the

muscles pull the lower jaw back, the interarch elastics are stretched, creating a distal force on the maxillary appliance and thus holding the upper posterior teeth in their original position. Cervical traction may also be extremely effective to retard mesial movement of molars. This is accomplished by placing buccal tubes on the high labial near the cribs to insert the bow.

Figure 10. Inter-arch elastic (*e*) make it possible to use the lower arch for additional anchorage for retruding the upper anterior teeth into the upper first premolar space. Note that the high labial arch wire (*h*) supports the elastic hooks as well as the pins to the anterior teeth.



Class II, Division 2 (Treatment Example)

Usually Division 2 cases have more inherent problems than do Division 1 cases. The major difference in treatment between Division 1 and Division 2 patients is that Division 1 patients are treated primarily by removing the maxillary anterior teeth lingually, whereas Division 2 patients are treated primarily by moving the mandibular incisors labially (Fig. 11). In treating Division 2 patients the same type of modified Crozat may be used to increase the vertical dimension immediately. In these cases, lingual auxiliaries and finger springs are used to tip the upper central and lower incisors labially. In uprighting the lingually inclined upper centrals, care should be taken not to move them too far labially because it may be difficult to establish contact with the incisal edges of the lower anterior teeth when the mouth is restored.

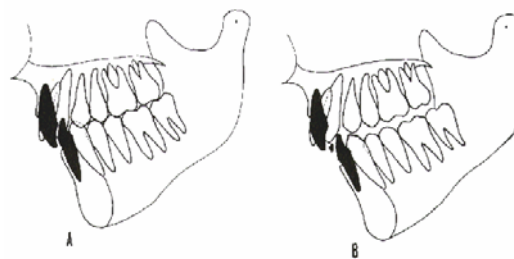


Figure 11. Cephalometric tracings show the relationship of the anterior teeth in Class II, Division 2. In A the lower incisors impinge on the palatal soft tissues, while the upper incisors impinge on the lower labial soft tissues. When the vertical dimension is increased (B), the lower anterior teeth can be tipped forward to make contact with the lingual fossae of the upper anterior teeth.

Sometimes in moving the lower anterior six teeth forward, enough space is created distal to the canines so that it is necessary to place a premolar pontic between the canine and the first premolar. If the upper anterior teeth or lower anterior teeth, or both, require extensive restoring because of caries and general breakdown, much of the space can be filled with these restorations. In severe cases, the teeth may require full crowns as well as tooth repositioning in order to meet the needs of a stable occlusion.

SUMMARY

The value of utilizing an orthodontic specialist in treating these patients cannot be overemphasized, but it should be borne in mind that the ultimate responsibility for the entire treatment belongs to the referring restorative dentist. Therefore, the restorative dentist must give to the orthodontist a detailed description as to where he wants the teeth to be positioned. At the same time, he should respect and appreciate the limitations of orthodontic treatment. Each case should be discussed in detail before and during treatment so that both orthodontist and restorative dentist know and understand the goals and limitations of the other.

Although the authors utilized a modified Crozat technique, they feel that other appliances may produce comparable results.⁵ It is suggested that the operator use any appliance which works well in his hands and yields the desired results. Often this requires modifications of basic techniques because of unique problems found in adults.

Frequently in discussions of complete prosthetics, mention has been made about the problem of encroachment on freeway space to a point where the patient is uncomfortable and complains of tired muscles, teeth colliding and so on. However, authors have not encountered this problem in the treatment of Class II deep bite patients, although the vertical dimension has, in some instances, been increased several millimeters in this region. These patients may not encounter discomfort due to the increased vertical dimension for two possible reasons: first, they are biting on soft acrylic splints or bite planes; secondly, the extended treatment periods necessary for tooth movement allow the patient to accommodate gradually.

Once these patients were orthodontically treated and the restoration completed, there was little need for a long retention period, except for some severely rotated anterior teeth. It is felt that the cusp-to-fossa arrangement of the occlusion acts to regain the posterior teeth, while the lips, tongue, and cheeks act to retain the anterior teeth – this may be termed functional retention.

CONCLUSIONS

1. To solve the problems of most Class II deep bite patients adequately, there must be an increase in the vertical dimension.
2. Increasing the vertical dimension in Class II cases accentuates the distal relationship of the mandible. This frequently necessitates the use of orthodontics to reposition the teeth in order to achieve a more satisfactory occlusion.
3. The splint-supported tooth movement has merit on the basis of time and economic and psychological aspects.
4. Restorative dentists who do not have sufficient time or training in tooth movement procedures should solicit the services of an orthodontist. However, it is the responsibility of the restorative dentist to give the orthodontist a detailed description as to where he wants the teeth positioned.

REFERENCES

-
- ¹ Stallard, H., and Stuart, C.E.: What kind of occlusion should recusped teeth be given? Dent. Clin. N. Amer., Nov., 1963
- ³ Wiebrecht, A.T.: Crozat Appliances in Maxillofacial Orthopedics. Milwaukee, Crown Ltd., 1966, pp. 21-53
- ² D'Amico, A.: The canine teeth. J.S. Calif. Dent. Asso., 26:1, 2 4, 5, 6 and 7, 1958
- ⁴ Ramfjord, S.P., and Ash, M. M.: Occlusion. Philadelphia, W.B. Saunders Company, 1966, p. 227.
- ⁵ Graber, T.M.; Orthodontics: Principles and Practice. Philadelphia, W. B. Saunders Company, 1966, pp. 740-789

22573 Barton Rd.
Colton, California 92324